

Perigraft seroma penetrating the aortic sac and rupturing into the intraperitoneal cavity

Magdalena Broda, MD, Jacob Budtz-Lilly, MD, Sten Vammen, MD, PhD, and Steen Fjord Pedersen, MD, PhD, Aarhus, Denmark

ABSTRACT

We present a case of a 66-year-old woman who developed perigraft seroma after having undergone elective, open abdominal aortic aneurysm repair with a polytetrafluoroethylene graft 5 years previously. One year after graft implantation, she started to suffer from abdominal discomfort and was therefore offered surgical intervention, which she declined owing to the fear of postoperative complications. Instead, an observational strategy was used. Five years later, the patient presented with sudden severe abdominal pain. Subsequent laparotomy revealed that the pseudomembrane lining the perigraft seroma had penetrated through the native aortic wall and into the intraperitoneal cavity, where it had ruptured. The patient was successfully treated by replacing the polytetrafluoroethylene graft with a polyethylene terephthalate (Dacron) graft. (*J Vasc Surg Cases and Innovative Techniques* 2019;5:298-301.)

Keywords: Perigraft seroma; Abdominal aortic aneurysm; Infection

A 61-year-old woman presenting with a symptomatic 5.5-cm infrarenal abdominal aortic aneurysm and an ectatic right common iliac artery underwent urgent repair in which an 18- × 9-mm aortobi-iliac bypass (polytetrafluoroethylene [PTFE], W. L. Gore & Associates, Flagstaff, Ariz) graft was used. Postoperative recovery was uneventful.

At the 1-year clinical follow-up, the patient complained of intermittent abdominal discomfort. The patient had also noticed that her abdomen had expanded since her discharge. An abdominal ultrasound examination was performed, revealing a fluid collection surrounding the graft. The patient was afebrile. The patient's leukocyte count and C-reactive protein were normal. A computed tomography (CT) scan showed an aortic aneurysm sac measuring 4 cm in diameter containing a fluid collection with an average radiodensity of 15 Hounsfield units. The CT scan also showed that the graft was intact with no signs of contrast extravasation or wall enhancement. There were no signs of other intra-abdominal pathology. Based on the blood sample results, clinical presentation and CT images, it was concluded that the patient had developed a perigraft seroma.

Because of abdominal discomfort, the patient was offered surgical intervention, but she declined owing to

fear of complications. Instead, an observational strategy was applied, and the patient was monitored with yearly clinical and abdominal ultrasound examinations. Subsequent follow-up revealed persistent expansion of the aneurysm sac and seroma. At the fifth postoperative year, ultrasound examination showed that the anterior-posterior diameter of the sac measured 10 cm. Because the patient was now experiencing considerable abdominal discomfort and pain, she agreed to undergo surgery, and a CT scan was performed to plan the operation strategy (Fig 1). However, the following day, the patient changed her mind and once again declined the operation owing to a fear of complications.

Two months later, the patient was admitted with acute right-sided severe abdominal pain. She was hemodynamically stable. An acute CT scan was repeated, revealing significant amounts of fluid in the peritoneal cavity (Fig 1).

At laparotomy, fluid was drained from the abdomen (Fig 2) and a perforated membrane measuring 10 cm in diameter and stretching into the peritoneal cavity through a tear in the aneurysm sac was identified (Fig 2). After systematic heparinization, the infrarenal aorta and common iliac arteries were clamped. The membrane was incised, and a large amount of yellow gelatinous material surrounding the PTFE graft was removed (Fig 2). The graft was not adherent to the surrounding tissues and was therefore easily separated. There was no sign of hematoma or active bleeding at the anastomoses, and there was no evidence of purulent fluid or visual sign of serum extravasation through the PTFE graft. The PTFE graft was removed and replaced with an 18- × 9-mm aortobi-iliac triclosan-coated polyethylene terephthalate (Dacron) graft (Intergard, Marquet, Rastatt, Germany). Part of the aortic sac was removed and the remaining aorta sac was closed around the new graft. Cultures from the fluid,

From the Department of Cardiothoracic and Vascular Surgery, Aarhus University Hospital.

Author conflict of interest: none.

Correspondence: Steen Fjord Pedersen, MD, PhD, Department of Vascular Surgery, Aarhus University Hospital, Palle Juul Jensen Blvd 99, 8200 Aarhus, Denmark (e-mail: fjord@mr.au.dk).

The editors and reviewers of this article have no relevant financial relationships to disclose per the Journal policy that requires reviewers to decline review of any manuscript for which they may have a conflict of interest.

2468-4287

© 2019 The Authors. Published by Elsevier Inc. on behalf of Society for Vascular Surgery. This is an open access article under the CC BY-NC-ND license (<http://creativecommons.org/licenses/by-nc-nd/4.0/>).

<https://doi.org/10.1016/j.jvscit.2019.03.020>

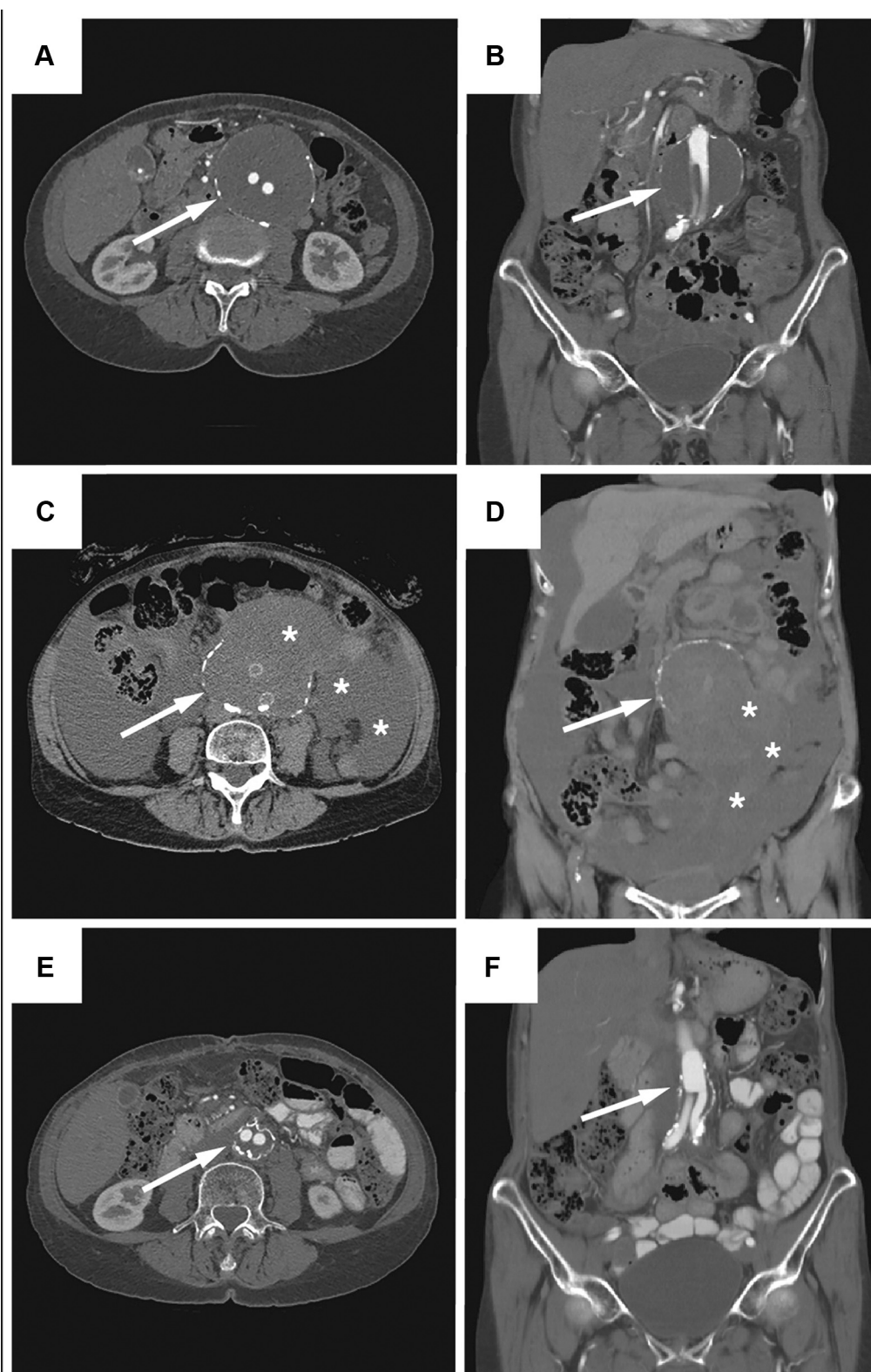


Fig 1. Representative images from computed tomography (CT) angiogram shows (A and B) the encapsulated perigraft seroma (arrow) with a diameter of 10 cm, and (C and D) the ruptured perigraft seroma (arrow) with free fluid in the intra-peritoneal cavity (*). E and F, Three months postoperative images showing no sign of perigraft seroma (arrow). (Printed with permission from the patient.)

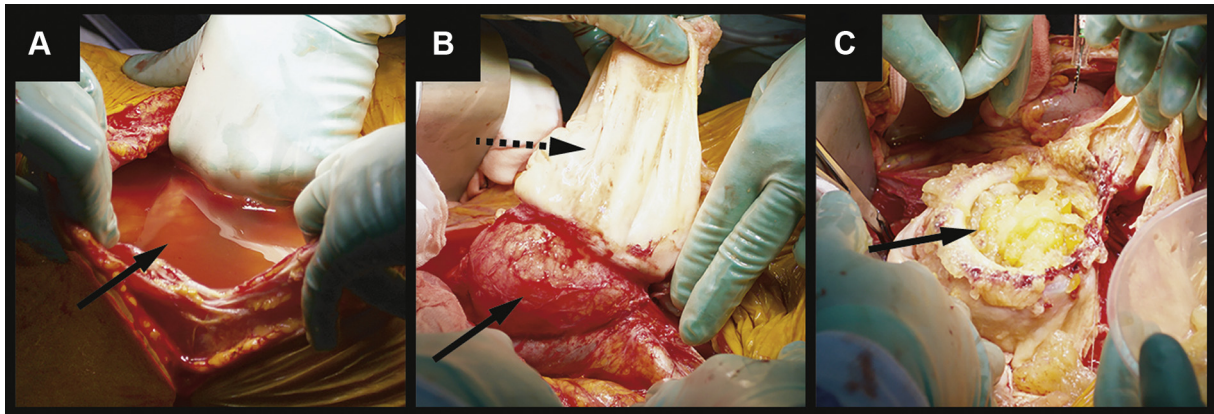


Fig 2. Perioperative photos. **A**, Free fluid in the intraperitoneal cavity (arrow). **B**, Seroma pseudomembrane (dotted arrow) extending from the ruptured native aneurysm sac (solid arrow). **C**, Contents of the perigraft seroma sac: a straw-coloured gelatinous mass (dotted arrow). (Printed with permission from the patient.)

pseudomembrane, gelatinous mass, and excised PTFE graft, were all negative.

The patient had an uneventful postoperative course and was discharged on postoperative day 9. At the 3-month follow-up, the patient was doing well without complaints and had returned to her normal life. The CT scan showed a patent graft with no sign of fluid accumulation (Fig 1). The patient's consent was obtained for this report.

DISCUSSION

Perigraft seroma is defined as a persistent, sterile collection of fluid confined within a nonsecretory, fibrous, pseudomembrane surrounding a vascular graft.¹² The condition is associated mainly with subcutaneously tunneled grafts,³⁻⁶ but is also a well-known complication of intra-abdominal grafts.⁷⁻¹¹ However, a perigraft seroma penetrating the aortic sac and rupturing into the intraperitoneal cavity, as described in this case, is very rare.

In this case, the patient developed perigraft seroma after PTFE grafting, which is congruent with existing literature, predominantly case reports describing perigraft seroma following PTFE graft implantation.^{3-5,12-14}

However, perigraft seroma has also been described for polyethylene terephthalate grafts, and a few cases also exist for vein¹ and stent grafts.¹⁵ The incidence of symptomatic perigraft seroma following open abdominal aortic aneurysm with PTFE graft has previously been reported to be 2.3% and the incidence of rupture to be 0.4%.¹²

The exact underlying etiology of perigraft seroma remains unknown. Yet, many authors believe that it is related to an immunologic reaction to the graft material, which activates a fibroblast inhibitor and prevents graft incorporation into the surrounding tissue. As a consequence, there is no tissue ingrowth into the graft pores, and graft porosity therefore remains high.¹⁶ Other suggested etiologies include low-grade infection, formation of biofilm, and physical damage to the graft.^{13,17}

Elimination of other possible pathologies such as infection, pseudoaneurysm, and bleeding is obligatory in establishing a diagnosis of perigraft seroma.

Various imaging techniques have been used for verifying the perigraft diagnosis, of which the most common are CT scan, ultrasound examination, and magnetic resonance imaging. In the present case, CT imaging was used as the first-line imaging modality, because it can both aid in the distinguishing of pathology as well as aid in the planning of the surgical approach. At our center, we use the following criteria to define perigraft seroma. First, the fluid collection has to be present more than three months following graft implantation. Second, the size of the fluid collection has to be at least 3 cm in diameter and, finally, we use a cutoff value greater than 25 Hounsfield units to differentiate seroma from hemorrhage.^{9,15} These criteria are in accordance with criteria suggested in previous literature.⁹

Therapeutic indications for perigraft seroma have not yet been clarified. Treatment aims to decrease symptoms, reduce recurrence, and avoid complications such as graft thrombosis, skin erosion, secondary graft infection, anastomotic aneurysm formation, and rupture.¹⁻³

In the present case, we initially used an observational strategy, particularly owing to the patient's concern for possible complications, despite her symptoms. Percutaneous aspiration is one option for relieving the pressure from the aortic sac and potential symptomatic relief, although there is a concern of secondary graft infection, which has been estimated to reach 8% to 12% in previous studies.¹⁸ Furthermore, it is well-known that perigraft seroma reappears shortly after aspiration if the membrane is not removed; therefore, this treatment only offers the patient temporary relief. It should also be noted that, in the present case, laparotomy revealed that the perigraft seroma consisted mainly of a gelatinous mass, which would have been impossible to aspirate through a needle.

It is commonly agreed that sac enlargement owing to perigraft seroma after open surgery is a relatively benign condition, and most authors recommend an observational strategy if the patient has no symptoms. Even in case of rupture, a conservative strategy can be used.¹⁷ However, in the present case, the patient was in severe pain and an operation was therefore performed. Also, we considered that as long as the PTFE graft remained in the patient it would keep producing the seroma and hence keep causing the patient abdominal pain. We chose to replace the original PTFE graft with a polyethylene terephthalate graft. This treatment strategy of replacing the original graft with a material different from the original one has previously been shown to be highly effective.¹⁸⁻²⁰

Alternative methods for graft preservation in patients with perigraft seroma after open abdominal aneurysm repair include omental transfer²¹ around the graft and endovascular relining of the prosthesis,^{14,15,22,23} but neither approach seems to be as effective as removal and replacement of the original graft.

Although perigraft seroma is a rare complication, most surgeons performing vascular graft implantation will encounter this complication during their professional career. For the surgeon to choose the best possible treatment strategy for this condition, basic knowledge about this condition is necessary.

REFERENCES

1. Blumenberg RM, Gelfand ML, Dale WA. Perigraft seromas complicating arterial grafts. *Surgery* 1985;97:194-204.
2. Dauria DM, Dyk P, Garvin P. Incidence and management of seroma after arteriovenous graft placement. *J Am Coll Surg* 2006;203:506-11.
3. Bissacco D, Domanin M, Romagnoli S, Gabrielli L. Perigraft seroma after extra-anatomic bypass: case series and review of the literature. *Ann Vasc Surg* 2017;44:451-8.
4. Bissacco D, Domanin M, Del Gobbo A, Gabrielli L. Giant Perigraft seroma after axillobifemoral bypass for Leriche's syndrome: a case report. *Ann Vasc Dis* 2016;9:252-4.
5. Buche M, Schoevaerdts JC, Jaumin P, Ponlot R, Chaland CH. Perigraft seroma following axillofemoral bypass: report of three cases. *Ann Vasc Surg* 1986;1:374-7.
6. Rhodes VJ. Perigraft seroma: simple solution to a difficult problem. *J Vasc Surg* 1986;3:939.
7. Ahn SS, Machleder HI, Gupta R, Moore WS. Perigraft seroma: clinical, histologic, and serologic correlates. *Am J Surg* 1987;154:173-8.
8. Wittenstein GJ. Complications of aortic aneurysm surgery: prevention and treatment. *Thorac Cardiovasc Surg* 1987;35:136-9.
9. Kadakol AK, Nypaver TJ, Lin JC, Weaver MR, Karam JL, Reddy DJ, et al. Frequency, risk factors, and management of perigraft seroma after open abdominal aortic aneurysm repair. *J Vasc Surg* 2011;54:637-43.
10. Williams GM. The management of massive ultrafiltration distending the aneurysm sac after abdominal aortic aneurysm repair with a polytetrafluoroethylene aortobiliac graft. *J Vasc Surg* 1998;28:551-5.
11. Wolff T, Koller MT, Eugster T, Rouden C, Marti R, Gürke L, et al. Endarterectomy of the aneurysm sac in open abdominal aortic aneurysm repair reduces perigraft seroma and improves graft incorporation. *World J Surg* 2011;35:905-10.
12. Thoo CHC, Bourke BM, May J. Symptomatic sac enlargement and rupture due to seroma after open abdominal aortic aneurysm repair with polytetrafluoroethylene graft: implications for endovascular repair and endotension. *J Vasc Surg* 2004;40:1089-94.
13. Salameh MK, Hoballah JJ. Successful endovascular treatment of aneurysm sac hygroma after open abdominal aortic aneurysm replacement: a report of two cases. *J Vasc Surg* 2008;48:457-60.
14. Sangawa K, Aoki A. Endovascular treatment of perigraft seroma after open abdominal aortic aneurysm repair: report of a case. *Ann Vasc Dis* 2013;6:218-20.
15. Risberg B, Delle M, Lönn L, Syk I. Management of aneurysm sac hygroma. *J Endovasc Ther* 2004;11:191-5.
16. Sladen JC, Mandl MA, Grossman L, Denegri JF. Fibroblast inhibition: a new and treatable cause of prosthetic graft failure. *Am J Surg* 1985;149:587-90.
17. Orion KC, Nicholson RM, Sharafuddin MJ, Kresowik TF, Corson J, Sharp WJ. A natural history of aortic aneurysm hygroma. *J Vasc Surg* 2011;54:1478-80.
18. Gazi A, Staffa R, Novotný T, Kriz Z, Hermanová M. Perigraft seroma as a rare angiosurgical complication. *Rozhl V Chir Mesicnik Ceskoslovenske Chir Spolecnosti* 2015;94:477-81.
19. Kaupp HA, Matulewicz TJ, Lattimer GL, Kremen JE, Celani VJ. Graft infection or graft reaction? *Arch Surg* 1979;114:1419-22.
20. Kondo Y, Muto A, Dardik A, Nishibe M, Nishibe T. Perigraft seroma after surgical aortoiliac aneurysm repair with knitted polyester grafts: report of two cases. *Ann Vasc Dis* 2009;2:44-6.
21. Stierli P, Gürke L, Hess P, Eugster, Harder F. Aneurysm sac enlargement after conventional inflammatory aneurysm repair with a polytetrafluoroethylene aortobiliac graft. *Eur J Vasc Endovasc Surg* 2000;20:484-6.
22. Ohtake H, Kimura K, Soga S, Sanada J, Matsui O, Watanabe G. Stent-graft deployment to treat a perigraft seroma formed after descending thoracic aortic surgery. *J Endovasc Ther* 2007;14:813-5.
23. Lachat M, Romero Toledo M, Glenck M, Veith FJ, Schmidt CA, Pecoraro F. Endoluminal stent-graft relining of visceral artery bypass grafts to treat perigraft seroma. *J Endovasc Ther* 2013;20:868-71.

Submitted Dec 18, 2018; accepted Mar 30, 2019.